

# The Comprehensive Anatomical Spinal Osteotomy Classification

Frank Schwab, MD\*  
 Benjamin Blondel, MD\*‡  
 Edward Chay, BA\*  
 Jason Demakakos, MS\*  
 Lawrence Lenke, MD§  
 Patrick Tropiano, MD‡  
 Christopher Ames, MD||  
 Justin S. Smith, MD, PhD¶  
 Christopher I. Shaffrey, MD¶  
 Steven Glassman, MD#  
 Jean-Pierre Farcy, MD\*\*  
 Virginie Lafage, PhD\*

\*NYU Hospital for Joint Diseases, New York, New York; ‡Orthopedic Department, Aix-Marseille University, Marseille, France; §Washington University School of Medicine, St. Louis, Missouri; ||Neurosurgery, University of California San Francisco, San Francisco, California; ¶Neurological Surgery, University of Virginia, Charlottesville, Virginia; #Spine Institute for Special Surgery, University of Louisville, Kentucky; \*\*Maimonides Medical Center, New York, New York

## Correspondence:

Virginie Lafage, PhD,  
 NYU Hospital for Joint Diseases, 306 E,  
 15th St, Suite 1F,  
 New York, NY 10003.  
 E-mail: virginie.lafage@gmail.com

Received, April 22, 2013.

Accepted, September 17, 2013.

Published Online, November 4, 2013.

Copyright © 2013 by the  
 Congress of Neurological Surgeons

**BACKGROUND:** Global sagittal malalignment is significantly correlated with health-related quality-of-life scores in the setting of spinal deformity. In order to address rigid deformity patterns, the use of spinal osteotomies has seen a substantial increase. Unfortunately, variations of established techniques and hybrid combinations of osteotomies have made comparisons of outcomes difficult.

**OBJECTIVE:** To propose a classification system of anatomically-based spinal osteotomies and provide a common language among spine specialists.

**METHODS:** The proposed classification system is based on 6 anatomic grades of resection (1 through 6) corresponding to the extent of bone resection and increasing degree of destabilizing potential. In addition, a surgical approach modifier is added (posterior approach or combined anterior and posterior approaches). Reliability of the classification system was evaluated by an analysis of 16 clinical cases, rated 2 times by 8 different readers, and calculation of Fleiss kappa coefficients.

**RESULTS:** Intraobserver reliability was classified as “almost perfect”; Fleiss kappa coefficient averaged 0.96 (range, 0.92-1.0) for resection type and 0.90 (0.71-1.0) for the approach modifier. Results from the interobserver reliability for the classification were 0.96 for resection type and 0.88 for the approach modifier.

**CONCLUSION:** This proposed anatomically based classification system provides a consistent description of the various osteotomies performed in spinal deformity correction surgery. The reliability study confirmed that the classification is simple and consistent. Further development of its use will provide a common frame for osteotomy assessment and permit comparative analysis of different treatments.

**KEY WORDS:** Adult spinal deformity, Classification, Osteotomy, Sagittal alignment

Neurosurgery 74:112–120, 2014

DOI: 10.1227/NEU.0000000000000182o

www.neurosurgery-online.com

It is now well established that sagittal and coronal plane spinal malalignment have an impact on pain and disability in adults.<sup>1–3</sup> In terms of surgical treatment, spinal osteotomies are increasingly applied for cases refractory to nonoperative care. Common pathologies that require such surgical approaches include adult scoliosis, flat back syndrome, iatrogenic fixed sagittal imbalance, kyphotic decompensation syndrome, and flat buttock. Among the realignment techniques used for these conditions, common techniques described in the literature include the Smith-Petersen osteotomy, Ponte osteotomy, pedicle

subtraction osteotomy, partial/total corpectomies, and vertebral column resections.<sup>4–9</sup>

Although several spinal osteotomy techniques are commonly discussed and reported in scientific publications, the variable use of terminology and substantial variations of resections are commonly noted. For example, there are several parallel names for the initially described osteotomy by Smith-Petersen<sup>6,8</sup> (opening wedge osteotomy, Chevron osteotomy, extension osteotomy). In addition, the evolution of osteotomy techniques has led to numerous procedures in which the difference is the degree of posterior element resection (Briggs,<sup>10</sup> polysegmental or Ponte osteotomies<sup>9,11</sup>), surgical approach, or pertinent pathology treated (Ponte osteotomy<sup>9,11</sup>). This variability in the application and description of osteotomy techniques lends itself to substantial

**ABBREVIATIONS:** P, posterior approach; A/P, combined anterior and posterior approaches; PSO, pedicle subtraction osteotomy

confusion and limitations in outcome analysis. For instance, it is not uncommon for Smith-Petersen and Ponte osteotomies to be used interchangeably, although the techniques are quite different. The comparison of response to treatment and analysis of complications between studies is markedly hampered if the interpretation of techniques is variable.

The struggle to standardize descriptions of techniques and interpretation of operative methods is not new. Ideally, such challenges are simplified by anatomically based approaches that offer a framework to group categories of procedures into related groups. An example of organizing pathology, for example, can be found in the Denis classification<sup>12</sup> system that established a “3-column” model—posterior, middle, anterior—to describe the complex pattern of injuries to the spinal column. However, this classification, although useful in anatomically describing destabilizing injury patterns to the spine, does not sufficiently describe the surgically induced “destabilization” of the spine, but offers a potential approach to grouping common osteotomy procedures.

Other areas of medicine have benefitted from classification systems such as the Glasgow coma scale,<sup>13</sup> and the revised trauma score,<sup>14</sup> or more recently the Tomita classification for spinal tumors,<sup>15</sup> which includes consideration of both the pattern of local vertebral tumor progression and the type of surgery used to excise it.

Likewise, we argue that a systematic and anatomically based approach toward spinal osteotomies is needed to facilitate communication by standardizing reporting and outcomes from treatment for spinal deformity. The aim of this study is to describe an anatomically based comprehensive classification of spinal osteotomies and to establish the inter- and intra-rater reliability of this new classification system.

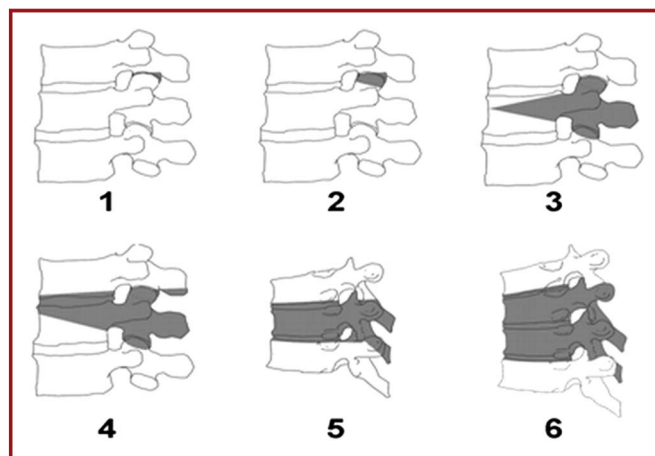
## PATIENTS AND METHODS

### Description of the Classification

This proposed osteotomy classification of spinal osteotomies (Figure 1 and Table 1) was designed to be anatomically based, graduated, and reasonably comprehensive. The classification system does not attempt to describe the indications, efficacy, or optimal surgical approaches of each procedure; instead, it is focused on offering a common language for anatomic resections. There are 6 proposed grades of resection (Figure 1) corresponding to different anatomic bone resections that reflect increasing degrees of potential destabilization. In addition, modifiers can be added to denote the surgical approach(es) but not the column of the spine that was destabilized (modifier P for posterior approach, modifier A/P for combined anterior and posterior approaches).

#### Grade 1: Partial Facet Joint Resection

**Description.** A grade 1 osteotomy (Figure 2) involves the resection of the inferior facet and joint capsule at a given spinal level. This procedure has limited deformity correction and is often applied to offer limited change in alignment and potential for fusion through cartilage removal of the superior facet. Anterior column mobility (nonfusion) is a prerequisite for performing a grade 1 osteotomy. Grade 1 osteotomies are done by using a posterior approach only (modifier P).



**FIGURE 1.** Osteotomy classification: grades 1 to 6 according to the anatomic resection.

**Published Techniques Associated With a Grade 1 Osteotomy.** An opening-wedge osteotomy, also known as the Smith-Petersen osteotomy,<sup>6,8</sup> has been described as involving multiple levels through previously fused articular processes of L1, L2, and L3 and adjacent spinous processes.<sup>16</sup> On average, 5° to 10° of correction can be achieved at each level, but a lack of anterior column mobility can lead to vascular and neurological sequelae.<sup>17</sup> Other terms commonly used to describe this type of osteotomy include the Chevron osteotomy<sup>18</sup> and the extension osteotomy,<sup>19</sup> which were described thru unfused facets.

#### Grade 2: Complete Facet Joint Resection

**Description.** In a grade 2 osteotomy (Figure 3), both inferior and superior facets of an articulation at a given spinal segment are resected, as well as the ligamentum flavum; other posterior elements of the vertebra including the lamina, or the spinous processes, may also be resected. Similar to grade 1, grade 2 osteotomies require preexisting anterior column mobility. Any osteotomies that remove bone from the vertebral body are excluded from this grade. Grade 2 osteotomies are commonly done by using a posterior approach alone (modifier P), but may also involve a combined anterior soft tissue (anterior longitudinal ligament and/or disc) release and may be further denoted by the modifier A/P.

**Published Techniques Associated With a Grade 2 Osteotomy.** Grade 2 osteotomies reflect resection of bone beyond what was described by Smith-Petersen. Briggs et al<sup>10</sup> described a procedure in which a single level wedge is removed that included the articular processes and upper pedicles. In the polysegmental osteotomy,<sup>20</sup> bone is removed from the articular processes and the interlaminar space adjacent to the articular processes. This is done at multiple levels to create a gradual lordosis. The Ponte procedure<sup>9,11</sup> is the resection of multiple facets along with the resection of the spinous processes and involves a substantial amount of bone and ligament resection to afford deformity correction. These osteotomies are thus termed grade 2 resections.

Burgos et al<sup>21</sup> described a procedure for pediatric thoracolumbar scoliosis using an anterior thoracoscopic approach. The procedure involves anterior release, discectomy, and fusion as well as concomitant posterior facet removal and fusion, corresponding to a modifier A/P in this classification.

**TABLE 1. Spinal Osteotomy Classification**

Anatomic Resection		Description	Surgical Approach Modifiers
Grade 1	Partial facet joint	Resection of the inferior facet and joint capsule at a given spinal level	P (posterior approach only)
Grade 2	Complete facet joint	Both superior and inferior facets at a given spinal segment are resected with complete ligamentum flavum removal; other posterior elements of the vertebra including the lamina, and the spinous processes may also be resected	P (posterior approach only) A/P (anterior soft tissue release combined with posterior resection)
Grade 3	Pedicle/partial body	Partial wedge resection of a segment of the posterior vertebral body and a portion of the posterior vertebral elements with pedicles	P (posterior approach only) A/P (both)
Grade 4	Pedicle/partial body/disc	Wider wedge resection through the vertebral body; includes a substantial portion of the posterior vertebral body, posterior elements with pedicles, and includes resection of at least a portion of 1 endplate with the adjacent intervertebral disc	P (posterior approach only) A/P (both)
Grade 5	Complete vertebra and discs	Complete removal of a vertebra and both adjacent discs (rib resection in the thoracic region)	P (posterior approach only) A/P (both)
Grade 6	Multiple vertebrae and discs	Resection of more than one entire vertebra and adjacent discs. Grade 5 resection and additional adjacent vertebral resection	P (posterior approach only) A/P (both)

### Grade 3: Pedicle and Partial Body Resection

**Description.** A grade 3 osteotomy (Figure 4) involves a partial wedge resection of the posterior vertebral body and the posterior elements with pedicles. A portion of the vertebral body and the discs above and below the level of the osteotomy remain intact. Grade 3 osteotomies can be further described as involving only a posterior approach (P) or combining approaches (A/P).

**Published Techniques Associated With a Grade 3.** The *pedicle subtraction osteotomy* (PSO) technique<sup>7</sup> has been described as a wedge-shaped resection of the pedicles extending into the posterior and middle portion of the vertebral body, following resection of both sets of articular processes and detachment of the transverse processes. With this technique, no anterior column lengthening is performed. According to Bridwell et al,<sup>18</sup> between 25° and 35° of correction can be reasonably achieved at any given level. Other terms applied to this osteotomy are the *closing wedge osteotomy*<sup>16</sup> and the *transpedicular wedge resection*.<sup>4</sup> This group of osteotomies falls within the category of grade 3P resection, because they are conducted via a posterior only approach. Of note, a PSO that extends into adjacent disc spaces would be termed a grade 4P resection (see later description).

The *circumferential wedge bone resection*<sup>22</sup> is another variant with a wedge-shaped apical vertebral body bone resection in addition to apical laminectomy and laminectomies of the vertebrae directly superior and inferior to the apex. Apical facets and pedicles are removed completely. Farcy and Schwab<sup>23</sup> described a similar resection, taking care to describe the process of removing each pedicle and adding instrumentation 1 side at a time for stability. These described variants are both grade 3 resections.

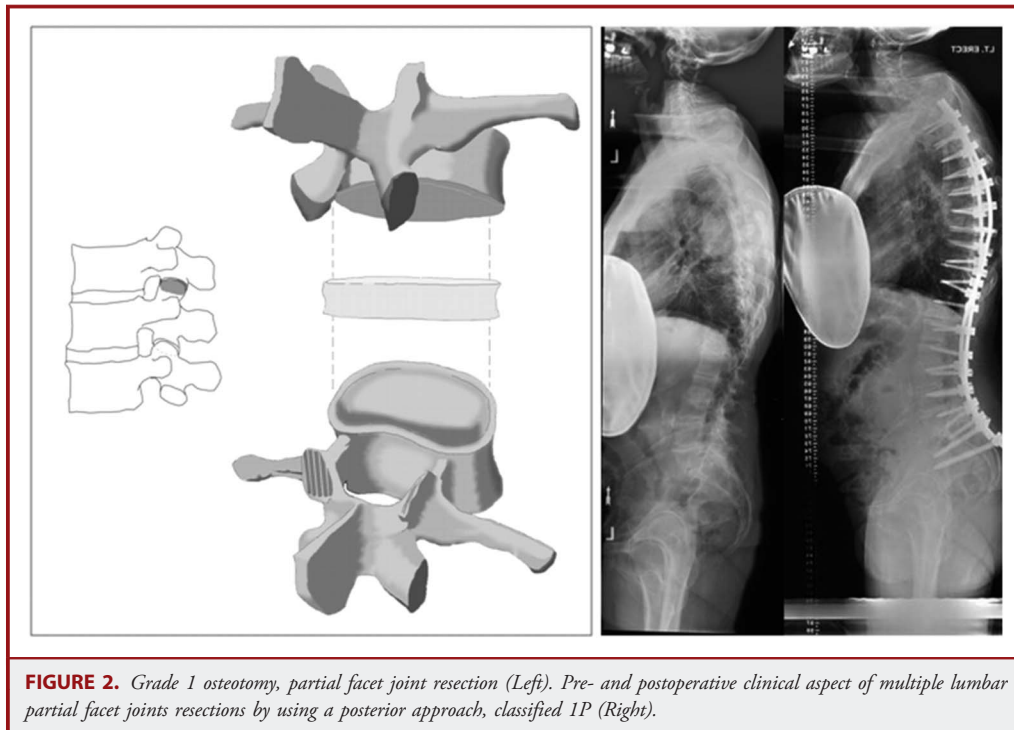
Similarly, the multilevel vertebral osteotomy described by Suh et al<sup>24</sup> involves facetectomies at all levels bilaterally with partial laminotomies at 1 or 2 levels proximal and distal to the apex. Osteotomies are then performed through laminectomy sites up to the anterior one-third of the vertebral body. Each osteotomy is a grade 3P resection.

A *closing opening wedge osteotomy*<sup>16</sup> is a posterior approach that provides more sagittal alignment correction than a PSO resection. The procedure requires the resection of the posterior elements while initially preserving the anterior, posterior, and lateral cortices of the vertebral body; the posterior cortex is then pushed into the body, and the anterior and lateral cortices are removed. This allows hinging to be over the posterior vertebral body rather than the anterior cortex, resulting in greater correction. This procedure is termed a grade 3P resection. A *simultaneous anterior and posterior approach*, as described by Pascal-Mousellard et al,<sup>25</sup> can be used to provide a similar resection, but with greater anterior control. This procedure is used primarily for revision surgery and would be classified as a grade 3A/P.

### Grade 4: Pedicle, Partial Body and Disc Resection

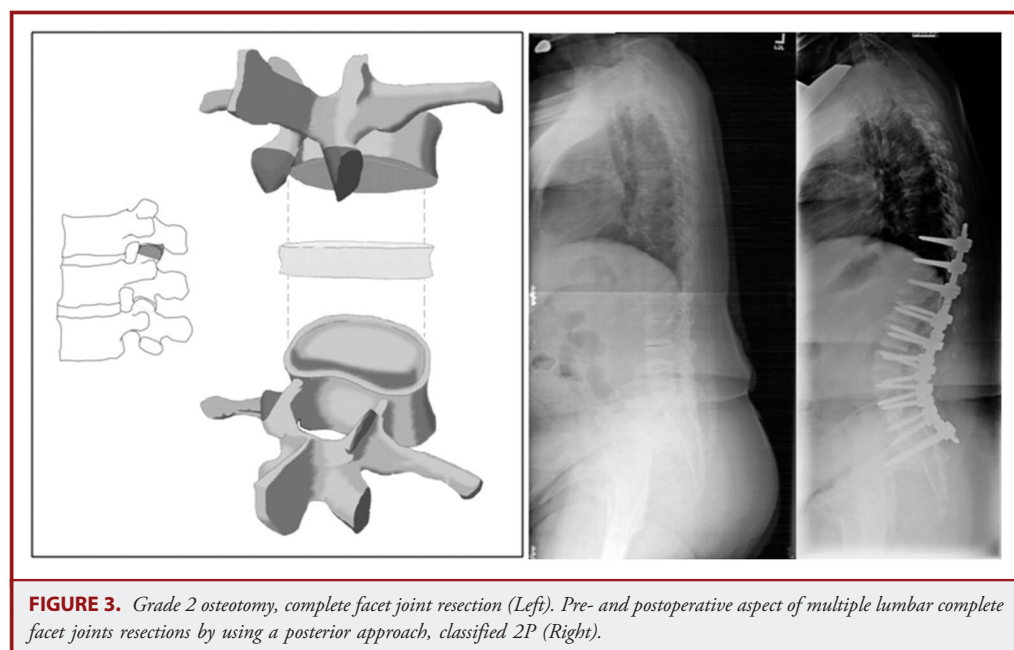
**Description.** In a grade 4 osteotomy (Figure 5), a wider wedge resection through the vertebral body is made than for a grade 3 and includes the posterior vertebral body, posterior elements with pedicles, and sufficient body resection such that an endplate and at least a portion of 1 adjacent disc (associated with a rib resection in the thoracic region) is removed. A portion of the vertebral body at the level of the osteotomy remains intact, but an anterior support may be necessary in cases of marked shortening. Grade 4 osteotomies can be further labeled as posterior release (P) or both (A/P).

**Published Techniques Associated With a Grade 4.** Scudese and Calabro<sup>26</sup> described a modified Smith-Petersen osteotomy with

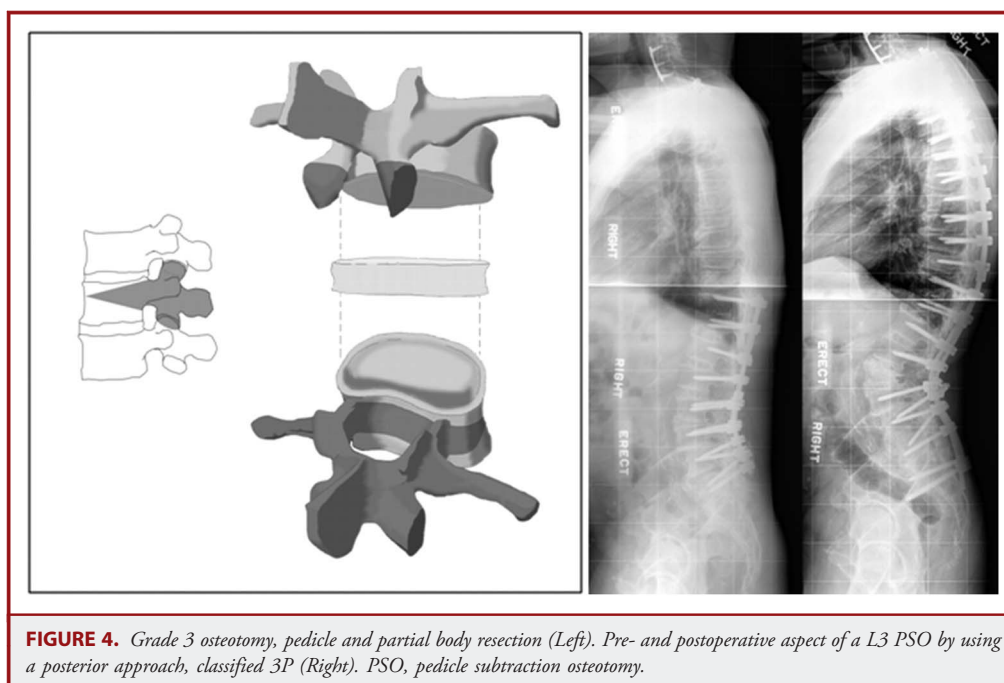


additional removal of the superior disc and superior portion of body, leading to less aortic or inferior vena cava obstruction secondary to stretching. This offers an equivalent amount of destabilization and correction potential as a pedicle subtraction osteotomy with disc resection described previously. These osteotomies are classified a grade 4P resection.

The *eggshell procedure*, originally described by Heinig,<sup>27</sup> was a technique that did not involve the disk space and would therefore be classified as grade 3. However, this procedure has been recently described<sup>28</sup> for realignment purposes with disc removal. Apical pedicles are decancellated, starting from the lateral walls. The medial pedicle walls and posterior wall of the vertebral body are preserved. After decancellation up through the adjacent disk space,







**FIGURE 4.** Grade 3 osteotomy, pedicle and partial body resection (Left). Pre- and postoperative aspect of a L3 PSO by using a posterior approach, classified 3P (Right). PSO, pedicle subtraction osteotomy.

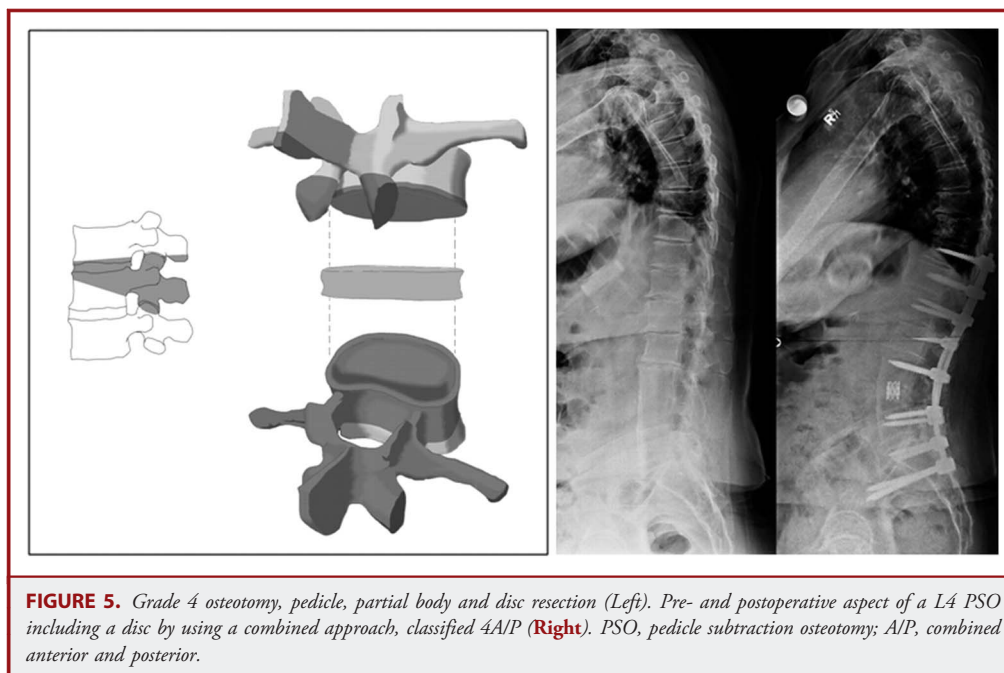
the preserved walls are removed, and the osteotomy is closed. This osteotomy, which includes a disc removal, is a grade 4P resection.

#### Grade 5: Complete Vertebra and Discs Resection

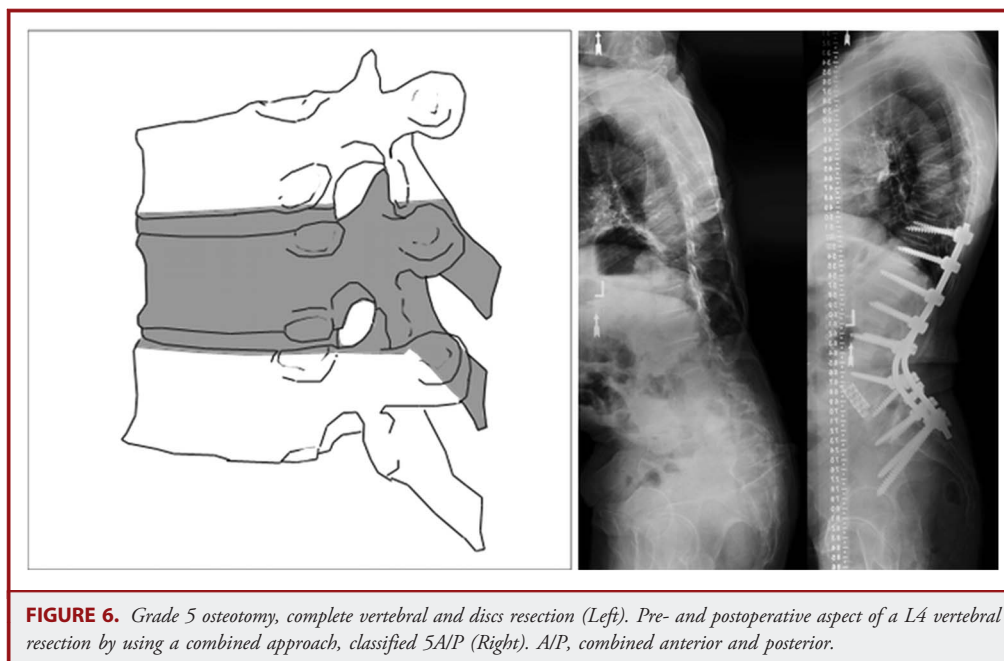
*Description.* The grade 5 osteotomy (Figure 6) involves the complete removal of a vertebral level and both adjacent discs and is associated with a rib resection in the thoracic region. Because of anterior shortening, anterior

support is frequently applied. Grade 5 osteotomies can be performed by anterior and posterior exposure to the spine and can thus be further defined as A/P, but are most commonly approached through posterior approaches only (modifier P) as reported by Lenke<sup>29</sup> and Suk et al<sup>30</sup>

*Published Techniques Associated With a Grade 5.* Vertebral column resection<sup>18</sup> involves the resection of one (grade 5) or more (grade 6) vertebral segments including posterior elements, pedicles, vertebral body,



**FIGURE 5.** Grade 4 osteotomy, pedicle, partial body and disc resection (Left). Pre- and postoperative aspect of a L4 PSO including a disc by using a combined approach, classified 4A/P (Right). PSO, pedicle subtraction osteotomy; A/P, combined anterior and posterior.



**FIGURE 6.** Grade 5 osteotomy, complete vertebral and discs resection (Left). Pre- and postoperative aspect of a L4 vertebral resection by using a combined approach, classified 5A/P (Right). A/P, combined anterior and posterior.

and discs cephalad and caudad to the apical vertebral body. This may be done either through a combined anterior and posterior approach, or posterior approach only.

Brodner et al<sup>31</sup> described an anterior approach involving resection of the apical vertebral body, as well as excision of the inferior and superior discs. The posterior elements are completely removed. The resulting resection is the same and can be labeled grade 5A/P.

#### Grade 6: Multiple Adjacent Vertebrae and Discs Resection

**Description.** In a grade 6 osteotomy (Figure 7), resection extends focally beyond the scope of a grade 5 resection. This type of osteotomy thus involves removal of several adjacent vertebrae, at least 1 complete vertebral body and a partial or complete second vertebra. Commonly, the osteotomy will involve multiple complete vertebrae, some of which may be only partially developed (eg, congenital malformation) or partially present (eg, infection/tumorous destruction or remodeling). The surgical approach will most commonly involve anterior and posterior approaches (modifier A/P) but a posterior-only approach is possible (modifier P). Substantial coronal and sagittal plane correction can be achieved with grade 6 osteotomies.

**Published Techniques Associated With a Grade 6.** Dubousset and Cotrel<sup>32</sup> described a procedure designed for children and adolescents for 3-dimensional corrections of spinal deformities. The procedure involves the removal of posterior elements and strategic decortication of concave side and instrumentation followed by the decortication of the convex side and instrumentation.

Dvorak et al<sup>33</sup> described an anterior spinal reconstruction following traumatic vertebral compression fractures in which multiple osteotomies are performed. The vertebral endplates are preserved following resection of vertebral bodies; a titanium mesh cylindrical cage is then installed and loosely filled with morselized autogenous bone graft.

#### Classification Reliability

Based on the classification outlined above, a reliability study was conducted with the use of 16 clinical cases (full-spine sagittal radiograph and portion of operative note), and graded by 8 fellowship-trained spinal surgeons with a practice focus on spinal deformity and working in different institutions. Two weeks approximately after the first reading, the grading was repeated with cases presented in a random order. Cases were selected to represent a wide distribution of osteotomy classification grades.

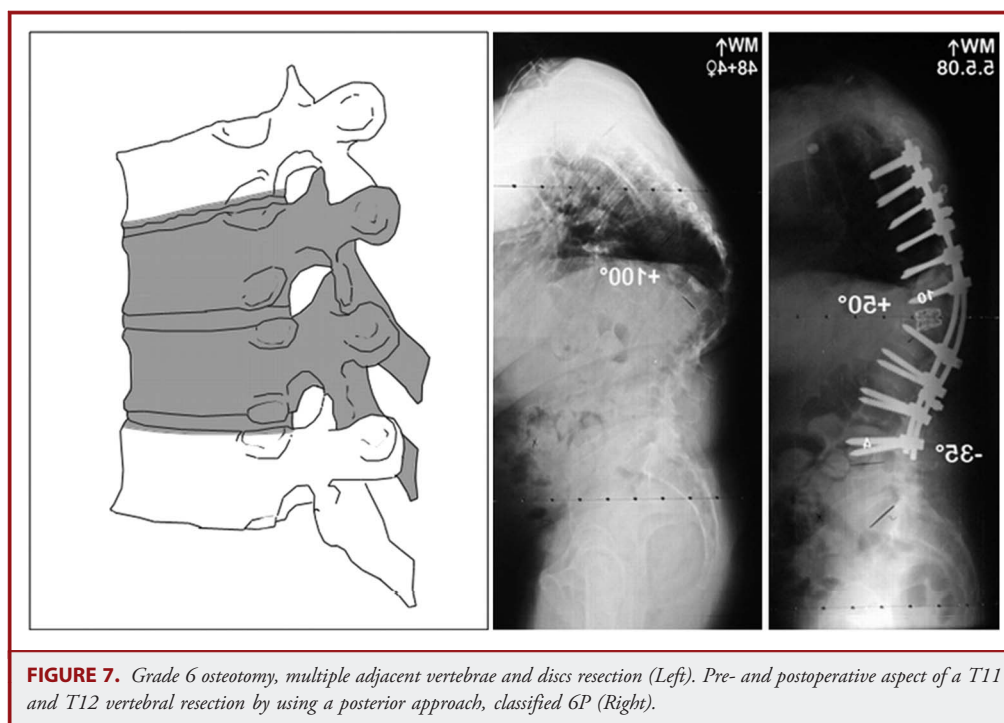
With the use of a dedicated MATLAB (Mathworks Inc, Natick, Massachusetts) program, interrater and intra-rater reliability measures were determined by calculating Fleiss kappa values. Kappa values of 0.00 to 0.20 were considered slight agreement, 0.21 to 0.40 fair agreement, 0.41 to 0.60 moderate agreement, 0.61 to 0.80 substantial agreement, and 0.81 to 1.00 almost perfect agreement.<sup>34</sup>

## RESULTS

#### Case Sample

Sixteen radiographic images, in association with excerpts of the corresponding operative notes, were compiled for assessment classification of resection type and approach modifier. Clinical cases were chosen in order to represent a wide range of situations and were classified as follows:

- Two cases were classified as grade 1 (modifier P)
- Three cases were classified as grade 2 (modifier P)
- Four cases were classified as grade 3 (2 modifier P and 2 A/P)
- Four cases were classified as grade 4 (2 modifier P and 2 A/P)
- Two cases were classified as grade 5 (modifier A/P)
- One case was classified as grade 6 (modifier A/P)



**FIGURE 7.** Grade 6 osteotomy, multiple adjacent vertebrae and discs resection (Left). Pre- and postoperative aspect of a T11 and T12 vertebral resection by using a posterior approach, classified 6P (Right).

### Intra-rater Reliability and Agreement

The intra-rater reliability of the resection grade and approach modifier was “almost perfect” with a Fleiss kappa coefficient average of 0.96 (range, 0.92-1.0) for the resection grade and 0.90 (range, 0.71-1.0) for the approach modifier (Table 2).

The comparison of the 2 sets of readings revealed that the resection type was graded consistently by each reader on average 96.8% of the time and the approach modifier 95.3% of the time. In 87.8% of cases, the readers assigned the same overall classification (grade + modifier) between readings.

### Interrater Reliability and Agreement

The interrater reliability for the resection grade and modifier was assessed for each reading. For resection grade, the Fleiss kappa

coefficient improved from 0.94 to 0.98 from the first to the second readings. The kappa values for the approach modifier improved from 0.86 to 0.90. As a whole, the interrater reliability for the classification was 0.96 for resection grade and 0.88 for the approach modifier (Table 3).

### DISCUSSION

Based on recent outcomes-related research, sagittal plane correction is of primary importance in the field of adult spinal deformity.<sup>2</sup> Restoration of satisfactory sagittal global alignment is increasingly a major surgical objective, and thresholds of correction have been reported by Schwab et al<sup>35</sup> as a pelvic tilt <25°, a sagittal vertical axis <50 mm, and a harmony between pelvic incidence and lumbar lordosis (defined by pelvic incidence minus lumbar lordosis <10°). Continued evolution of our understanding of adult spinal deformity management and the critical analysis of health-related quality-of-life scores has led to an increase in the use of long fusions and posterior osteotomies.

Over the past decades, a substantial number of spinal osteotomy techniques have been described in the literature. In addition, variations of established techniques are commonly performed. An emerging need has surfaced regarding accurately describing anatomic resections performed in the setting of spinal deformity correction by osteotomy. In the absence of an anatomically based and standardized approach to osteotomies, the analysis of outcomes and comparison of results through a common language between colleagues is not feasible.

Any osteotomy of the spine performed with the goal of achieving improved alignment involves some degree of resection,

**TABLE 2. Intra-rater Reliability—Fleiss Kappa Value for Resection Grade and Approach Modifier for Each Reader Based on the Two Readings**

	Resection Type	Approach Modifier
Reader 1	0.92	1.00
Reader 2	0.92	0.71
Reader 3	1.00	1.00
Reader 4	1.00	0.73
Reader 5	0.92	1.00
Reader 6	1.00	1.00
Reader 7	1.00	0.87
Reader 8	0.92	0.87
Average	0.96	0.90

**TABLE 3. Interrater Reliability—Fleiss Kappa Value for Resection Grade and Approach Modifier Based on the Two Readings**

	Resection Type	Approach Modifier
Reading 1	0.94	0.86
Reading 2	0.98	0.90
Average	0.96	0.88

which can be viewed as a wedge defined by the anatomic components and angle of resection. Changing these 2 parameters essentially determines the anatomic landmarks by which to define the grades of a classification. This is true for grades 1 through 4 in the proposed classification system, whereas grades 5 and 6 involve entire vertebral segments.

This classification system based on spinal anatomy can describe most clinical situations. The use of this classification system is consistent and reliable, as demonstrated by the high agreement of readings in the reliability study.

However, there are some exceptional cases that do not fit as neatly into the anatomic system proposed. LaChapelle<sup>36</sup> described a case involving the removal of facets as well as portions of other posterior elements. A wedge of disc was also removed, while the vertebral body remained intact. Although this case resulted in symptomatic relief, it is not commonly performed owing to a lack of stability and minimal correction. The complete removal of the posterior arch while leaving the vertebral body intact could eventually be associated to a grade 2 but would not capture the posterior partial discectomy.

Majd et al<sup>37</sup> described an *anterior corpectomy* for surgical reconstruction of the vertebral body following traumatic compression injury. In this procedure, resection of collapsed vertebral bodies and discs superior and inferior is performed via a retroperitoneal approach. The lateral and posterior portions of the vertebral body are preserved and anterior instrumentation is applied. By definition, this partial vertebral body and disc resection does not fit the grade 4A/P because of the anterior nature of the approach. It must be noted, however, that the resection is not wedge shaped as would be expected for deformity correction.

Despite some of the limitations inherent in any classification system, the proposed approach offers substantial advantages over current terminology. By offering a graded scale of anatomic destabilization, variations in technique are accounted for, yet comparative analysis is permitted. The addition of the approach modifiers furthermore permits differentiation of surgical procedures and is tied to case complexity as well as the risk for complications. It is hoped that adoption of the proposed classification, as for the Lenke adolescent idiopathic scoliosis classification,<sup>38</sup> will enhance the ability to analyze collective data sets by increasing consistency in the description of osteotomies and comparative analysis of surgical outcomes.

## CONCLUSION

The proposed comprehensive anatomic classification system of spinal osteotomies, based on 6 resection grades and an approach modifier, provides a consistent description of the various osteotomies performed in the field of spinal deformity. Results of the reliability study revealed almost perfect intra- and interrater agreement, confirming that this classification system is simple and consistent. Further development of its use will provide a common framework for osteotomy assessment and will permit comparative analysis of different treatments for spinal deformity.

## Disclosures

Dr Ames reported the following disclosures: Consultant (DePuy, Medtronic, Stryker), Royalties (Aesculap, Lanx), Stock Options (Trans1, Doctor's research group, Visualase). Dr Blondel: Consultant (Medicrea), Jean-Pierre Farcy: Lectures (DePuy). Dr Glassman: Consultant (Medtronic), Board Membership (Medtronic), Employment (Norton Healthcare), Patents/Royalties (Medtronic). Dr Lafage: Consultant (Medtronic), Lectures (Medtronic, DePuy, K2M), StockHolder (Nemaris Inc). Dr Lenke: Travel Accommodation (Medtronic, BroadWater, SRS), Board Membership (SRS, Spine, Journal Spinal Disorders and Techniques, The Spine Journal, Back Talk, Journal Neurosurgery Spine), Grants (Axial Biotech, DePuy), Royalties (Medtronic, Quality Medical Publishing). Dr Schwab: Consultant (Medtronic), Royalties (Medtronic), Lectures (Medtronic, DePuy), Research Support (DePuy, NIH), StockHolder (Nemaris Inc), Christopher Shaffrey: Consultant (Medtronic, Biomet, Nuvasive), Royalties (Medtronic, Biomet), Patent Holder (Medtronic, Biomet), Educational Consultant (Globus, Stryker), Grants (NIH, AO, NREF, DOD, NACTN). Dr Smith: Consultant (Biomet, Medtronic, DePuy), Honorarium (Biomet, Medtronic, DePuy, Globus), Research Support (DePuy). Dr Tropiano: Consultant (Synthes), Royalties (LDR Medical), Edward Chay and Jason Demakakos: None.

## REFERENCES

- Glassman SD, Berven S, Bridwell K, Horton W, Dimar JR. Correlation of radiographic parameters and clinical symptoms in adult scoliosis. *Spine (Phila Pa 1976)*. 2005;30(6):682-688.
- Lafage V, Schwab F, Patel A, Hawkinson N, Farcy JP. Pelvic tilt and truncal inclination: two key radiographic parameters in the setting of adults with spinal deformity. *Spine (Phila Pa 1976)*. 2009;34(17):E599-E606.
- Schwab F, Farcy JP, Bridwell K, et al. A clinical impact classification of scoliosis in the adult. *Spine (Phila Pa 1976)*. 2006;31(18):2109-2114.
- Boachie-Adjei O, Ferguson JA, Pigeon RG, Peskin MR. Transpedicular lumbar wedge resection osteotomy for fixed sagittal imbalance: surgical technique and early results. *Spine (Phila Pa 1976)*. 2006;31(4):485-492.
- Bridwell KH, Lewis SJ, Rinella A, Lenke LG, Baldus C, Blanke K. Pedicle subtraction osteotomy for the treatment of fixed sagittal imbalance. Surgical technique. *J Bone Joint Surg Am*. 2004;86-A (suppl 1):44-50.
- Smith-Petersen MN, Larson CB, Aufranc OE. Osteotomy of the spine for correction of flexion deformity in rheumatoid arthritis. *Clin Orthop Relat Res*. 1969;66:6-9.
- Thomassen E. Vertebral osteotomy for correction of kyphosis in ankylosing spondylitis. *Clin Orthop Relat Res*. 1985(194):142-152.
- Smith-Petersen MN, Larson C, Aufranc OE. Osteotomy of the spine for correction of flexion deformity in rheumatoid arthritis. *J Bone Joint Surg Am*. 1945; 27(1):1-11.
- Ponte A. Posterior column shortening for Scheuermann's kyphosis: an innovative one-stage technique. In: Maher T, Merola AA, eds. *Surgical Techniques for the Spine*. New York, NY: Thieme Medical; 2003:107-113.
- Briggs H, Keats S, Schlesinger PT. Wedge osteotomy of the spine with bilateral intervertebral foraminotomy; correction of flexion deformity in five cases of ankylosing arthritis of the spine. *J Bone Joint Surg Am*. 1947;29(4):1075-1082.



11. Geck MJ, Macagno A, Ponte A, Shuffelbarger HL. The Ponte procedure: posterior only treatment of Scheuermann's kyphosis using segmental posterior shortening and pedicle screw instrumentation. *J Spinal Disord Tech*. 2007;20(8):586-593.
12. Denis F. The three column spine and its significance in the classification of acute thoracolumbar spinal injuries. *Spine (Phila Pa 1976)*. 1983;8(8):817-831.
13. Teasdale G, Jennett B. Assessment of coma and impaired consciousness. A practical scale. *Lancet*. 1974;2(7872):81-84.
14. Champion HR, Sacco WJ, Copes WS, Gann DS, Gennarelli TA, Flanagan ME. A revision of the Trauma Score. *J Trauma*. 1989;29(5):623-629.
15. Tomita K, Kawahara N, Murakami H, Demura S. Total en bloc spondylectomy for spinal tumors: improvement of the technique and its associated basic background. *J Orthop Sci*. 2006;11(1):3-12.
16. Chang KW, Cheng CW, Chen HC, Chang KI, Chen TC. Closing-opening wedge osteotomy for the treatment of sagittal imbalance. *Spine (Phila Pa 1976)*. 2008;33(13):1470-1477.
17. Yang BP, Ondra SL, Chen LA, Jung HS, Koski TR, Salehi SA. Clinical and radiographic outcomes of thoracic and lumbar pedicle subtraction osteotomy for fixed sagittal imbalance. *J Neurosurg Spine*. 2006;5(1):9-17.
18. Bridwell KH. Decision making regarding Smith-Petersen vs. pedicle subtraction osteotomy vs. vertebral column resection for spinal deformity. *Spine (Phila Pa 1976)*. 2006;31(19 suppl):S171-S178.
19. Lu DC, Chou D. Flatback syndrome. *Neurosurg Clin N Am*. 2007;18(2):289-294.
20. Sansur CA, Fu KMG, Oskoui RJ Jr, Jagannathan J, Kuntz C, Shaffrey CI. Surgical management of global sagittal deformity in ankylosing spondylitis. *Neurosurg Focus*. 2008;24(1):E8.
21. Burgos J, Rapariz JM, Gonzalez-Herranz P. Anterior endoscopic approach to the thoracolumbar spine. *Spine (Phila Pa 1976)*. 1998;23(22):2427-2431.
22. Shimode M, Kojima T, Sowa K. Spinal wedge osteotomy by a single posterior approach for correction of severe and rigid kyphosis or kyphoscoliosis. *Spine (Phila Pa 1976)*. 2002;27(20):2260-2267.
23. Farcy JP, Schwab F. Posterior osteotomies with pedicle subtraction for flat back and associated syndromes. Technique and results of a prospective study. *Bull Hosp Jt Dis*. 2000;59(1):11-16.
24. Suh SW, Modi HN, Yang J, Song HR, Jang KM. Posterior multilevel vertebral osteotomy for correction of severe and rigid neuromuscular scoliosis: a preliminary study. *Spine (Phila Pa 1976)*. 2009;34(12):1315-1320.
25. Pascal-Mousellard H, Klein JR, Schwab FJ, Farcy JP. Simultaneous anterior and posterior approaches to the spine for revision surgery: current indications and techniques. *J Spinal Disord*. 1999;12(3):206-213; discussion 214.
26. Scudese VA, Calabro JJ. Vertebral wedge osteotomy. Correction of rheumatoid (ankylosing) spondylitis. *JAMA*. 1963;186:627-631.
27. Heinig CA. Eggshell procedure. In: Luque ER, ed. *Segmental Spinal Instrumentation*. Thorofare, NJ: Slack; 1984:221-230.
28. Murrey DB, Brigham CD, Kiezbak GM, Finger F, Cheurning SJ. Transpedicular decompression and pedicle subtraction osteotomy (eggshell procedure): a retrospective review of 59 patients. *Spine (Phila Pa 1976)*. 2002;27(21):2338-2345.
29. Lenke LG. Kyphosis of the thoracic and thoracolumbar spine in the pediatric patient: prevention and treatment of surgical complications. *Instr Course Lect*. 2004;53:501-510.
30. Suk SI, Kim JH, Lee SM, Chung ER, Lee JH. Anterior-posterior surgery versus posterior closing wedge osteotomy in posttraumatic kyphosis with neurologic compromised osteoporotic fracture. *Spine (Phila Pa 1976)*. 2003;28(18):2170-2175.
31. Brodner W, Mun Yue W, Möller HB, Hendricks KJ, Burd TA, Gaines RW. Short segment bone-on-bone instrumentation for single curve idiopathic scoliosis. *Spine (Phila Pa 1976)*. 2003;28(20):S224-S233.
32. Dubousset J, Cotrel Y. Application technique of Cotrel-Dubousset instrumentation for scoliosis deformities. *Clin Orthop Relat Res*. 1991;264:103-110.
33. Dvorak MF, Kwon BK, Fisher CG, Eiserloh HL 3rd, Boyd M, Wing PC. Effectiveness of titanium mesh cylindrical cages in anterior column reconstruction after thoracic and lumbar vertebral body resection. *Spine (Phila Pa 1976)*. 2003;28(9):902-908.
34. Landis JR, Koch GG. The measurement of observer agreement for categorical data. *Biometrics*. 1977;33(1):159-174.
35. Schwab F, Patel A, Ungar B, Farcy JP, Lafage V. Adult spinal deformity-postoperative standing imbalance: how much can you tolerate? An overview of key parameters in assessing alignment and planning corrective surgery. *Spine (Phila Pa 1976)*. 2010;35(25):2224-2231.
36. La CHAPELLE EH. Osteotomy of the lumbar spine for correction of kyphosis in a case of ankylosing spondylarthritis. *J Bone Joint Surg Am*. 1946;28(4):851-858.
37. Majd ME, Vadha M, Holt RT. Anterior cervical reconstruction using titanium cages with anterior plating. *Spine (Phila Pa 1976)*. 1999;24(15):1604-1610.
38. Lenke LG, Betz RR, Harms J, et al. Adolescent idiopathic scoliosis: a new classification to determine extent of spinal arthrodesis. *J Bone Joint Surg Am*. 2001;83-A(8):1169-1181.

## COMMENTS

Given the recent interest and growth in spinal deformity surgery, this proposed classification system is particularly relevant. The classification system is logical, straightforward, and appears to have a high rate of intraobserver and interobserver reliability, which are key components of a good classification scheme. As the authors highlight, a classification system is needed to accurately perform meaningful comparative analyses of various treatments for adult spinal deformity.

**Paul Park**  
Ann Arbor, Michigan

The authors have proposed a classification schema for surgical treatments directed at managing adult spinal deformities. Because neurosurgeons have been treating these disorders more frequently, the publication of their study is quite appropriate for *Neurosurgery*. The scheme was centered on the degree of spinal destabilization created by using bony osteotomies. As such, they proposed 6 grades of progressive bony resection. In brief, grades 1 to 2 involved facet joint resection, as seen with Smith-Petersen osteotomies; grades 3 to 4 were 3-column osteotomies that were variants of a pedicle subtraction osteotomy; and grades 5 to 6 were vertebral column resections. Grades 2 to 6 could be approached from posterior or with a supplemental anterior stage as well.

The authors then validated its ease of applicability and interrater agreement by using 16 cases presented to 8 spinal surgeons. Overall, the degree of agreement was excellent, with greater than 95% agreement between the different surgeons. This finding is critical, because surgeon clinicians and researchers must be able to easily "speak the same language." Other previous classification systems, such as the AO fracture classification scheme, have been highly descriptive, yet unwieldy and difficult to apply in clinical practice. This scheme does not appear to suffer from that problem. Furthermore, the system can be applied to open vs minimally invasive surgery, focusing not on the surgical technique but instead on the intended mechanical goal.

This study also has the potential to generate a deeper understanding of the goals and techniques for spinal deformity surgery for the wider community of neurosurgeons. Simply having the classification system at hand will prompt the clinician to approach each case in a more structured and organized format. For example, one can easily see that, by using such a system, factors such as the degree of spinal stiffness and the degree of lordosis that must be introduced to achieve sagittal plane balance can be approached almost algorithmically. I suspect that future studies will examine the application of this grading scheme in just such a manner and that radiographic data analysis software, such as Scolisoft will be able to integrate the grading to assist with surgical planning.

In summary, the use of standardized classification system for spinal osteotomies is a useful tool for the researcher or clinician to improve understanding the disease states and our surgical remedies. This study is a step in the right direction. The classification scheme was easy to understand and use, and it has significant clinical relevance. I congratulate the authors on their contribution to the field.

**Michael Y. Wang**  
Miami, Florida